

EQUINE MEDICAL CENTER OF OCALA

7107 West Highway 326 Phone: (352) 873-7830 www.emcOcala.com
Ocala, Florida 34482 Fax: (352) 873-7700

RADIOGRAPHIC EXAMINATION CERTIFICATE

Consignor: Harris

Name: '19 Miss Meteor X Peace and Justice

Date: May 11, 2021

History: Radiographic examination of carpi, tarsi, fore and hind fetlocks, and stifles.

Provisional Diagnosis: No significant abnormalities identified

Interpretation:

Left front fetlock:	No abnormal findings
Right front fetlock:	No abnormal findings
Left hind fetlock:	No abnormal findings
Right hind fetlock:	No abnormal findings
Left knee:	No abnormal findings
Right knee:	No abnormal findings
Left hock:	No abnormal findings
Right hock:	No abnormal findings
Left stifle:	No abnormal findings
Right stifle:	No abnormal findings

Patrick C. Worden, D.V.M.

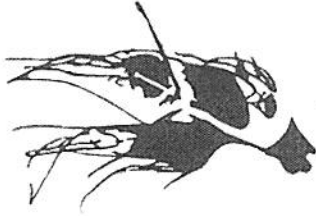


Fasig-Tipton

Date: 5/12/2021

Time: 12:36 PM ET

Initial: JO



EQUINE MEDICAL CENTER OF OCALA

7107 West Highway 326 Phone: (352) 873-7830 www.emcOcala.com
Ocala, Florida 34482 Fax: (352) 873-7700

ENDOSCOPIC EXAMINATION CERTIFICATE

Consignor: Harris Training **Name:** '19 Mis Meteor X Peace and Justice **Date:** May 7, 2021

History: Pre-sale endoscopic examination of upper airway

Provisional Diagnosis: No significant abnormalities identified

Subjective Grade: **A**

Normal structure and function to larynx
synchronous and symmetric abduction to arytenoids; can fully abduct readily
and maintain abduction; Good epiglottis

I have on this day performed an endoscopic exam of the upper airway on the above mentioned horse.
This is an opinion and not a warranty.

Patrick C. Worden, D.V.M.